

## SQUAMOUS CELL CARCINOMA OF THE MASTOID – A REPORT OF TWO CASES

\*O.A. LASISI, A.O. OGUNLEYE AND E.E.U. AKANG

Departments of Otorhinolaryngology and Pathology, University of Ibadan, P.O. Box 22040, Ibadan, Nigeria.

### SUMMARY

Malignant tumours of the mastoid are rare, the majority being squamous cell carcinomas. We report two cases whose clinical presentation mimicked mastoid abscess with intracranial complications. The first case is a twenty year Nigerian lady who presented to the Emergency Room of the Otorhinolaryngology Department with a one month history of headache, low grade fever, left facial palsy, neck stiffness and left post-auricular swelling on a background of left chronic suppurative otitis media since childhood. An initial diagnosis of meningitis and mastoid abscess secondary to chronic suppurative otitis media was made but histology of the mastoid specimen revealed keratinizing squamous cell carcinoma, which was treated with palliative primary radiotherapy. The second case is a 45-year old man with a chronic mastoiditis and mastoid abscess that was later found to be squamous cell carcinoma of the mastoid and was managed with combination of surgery and radiotherapy. The report highlights advanced stage of the disease at presentation, and discusses the etiology and management. To the best of our knowledge, these are the first cases of this entity to be documented in Africans.

**Keywords:** Squamous cell carcinoma, middle ear, mastoid, abscess.

### INTRODUCTION

Malignant tumours of the mastoid and middle ear as a groups are rare, accounting for 5 to 26% of all ear neoplasms<sup>1-3</sup>. Of these neoplasms, squamous cell carcinoma is the most common, with an age-adjusted incidence of 1 case in 1 million and peak age of 60 years<sup>1-3</sup>.

The major etiological factor is chronic suppurative otitis media<sup>1-4</sup> although irradiation and inverted

papilloma of the middle ear have also been reported to be additional risk factors<sup>1,2,5</sup>. The relative frequency of chronic otitis media in two different studies of cancer of the middle ear cleft was reported to be 85% and 28% respectively, which strongly suggests a relationship between otitis media and aural cancer<sup>2,3</sup>. In a recent report, human papilloma virus types 16 and 18 have been associated with squamous cell carcinoma of the middle ear at both tissue and molecular levels, thus providing a good model to explain the pathogenesis of chronic inflammation-related human malignancies<sup>4</sup>.

The classical treatment is combined surgery and radiotherapy, although either method may be used alone<sup>1,2</sup>. However, clinical responses have been reported with repeated administration of recombinant Interleukin 2 around tumour-draining lymph nodes<sup>6</sup>.

Literature review shows that this is the first case report in Africa. This article highlights the dilemma of diagnosis and the management of this disease.

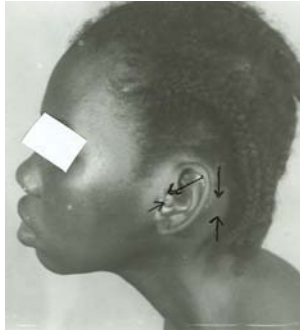### Case 1

A 20-year-old single lady presented at the Emergency Room of the Hospital with a 14-year history of recurrent left ear discharge, which worsened six months before presentation. There was associated severe deep-seated left otalgia, left hemi-cranial headache, hearing loss, vertigo and tinnitus. Three months prior to presentation, a swelling was noticed in the left external auditory canal (EAC) and posterior auricular area which was increasing in size progressively and associated with left bloody otorrhea, progressive left facial palsy and neck stiffness. No associated nasal, visual or throat symptoms were elicited.

---

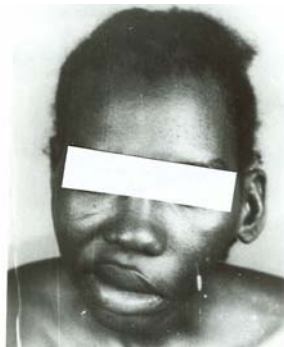\* Author for correspondence

Examination revealed a febrile and cachectic young lady with neck stiffness. There was a soft fleshy growth in the left EAC with mucopurulent secretion, and a left mastoid swelling which was firm but had some fluctuant areas (Figure 1a).



**Figure 1a** Left lateral view of the face showing fleshy soft tissue mass jutting out through the external auditory meatus and post-auricular swelling

The mastoid swelling was hyperaemic, tender and warm. Needle aspiration revealed seropurulent fluid with friable debris. Microbiologic culture of this aspirate did not yield any growth. There was left facial nerve palsy lower motor neuron type and neck stiffness (Figure 1b). The submandibular and jugulodigastric lymph nodes were palpable, discrete, mobile and non-tender, measuring about 1 x 2cm in diameter. The tuning fork tests suggested left conductive hearing loss.

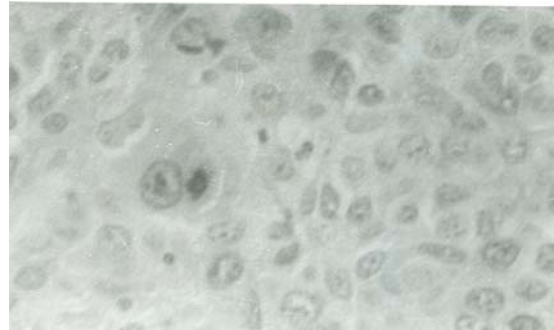


**Figure 1b** Frontal view of the face showing left lower motor neuron facial nerve palsy

A diagnosis of left chronic suppurative otitis media, complicated by aural polyp, mastoid abscess and meningitis was made, to rule out an intracranial mass lesion. An emergency incision and

drainage of the mastoid abscess was done under local anaesthesia. Purulent secretions mixed with keratinous debris and fleshy tissues were removed creating a communication between the left EAC and the mastoid cavity, which was about 2cm deep. The specimen was sent for histopathological examination and microbiologic culture. The patient was commenced on intravenous co-amoxiclav, oral paracetamol/dextropropoxyhene and hematinics.

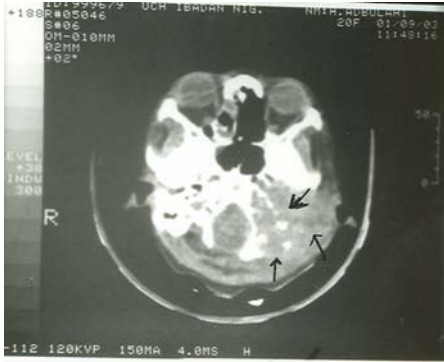The microbiologic culture of the mastoid aspirate revealed no growth while histological examination of the tissue biopsy revealed a keratinizing squamous cell carcinoma with features suggestive of Human Papilloma Virus (HPV) infection, although tissue culture for HPV proved negative (Figure 1c).



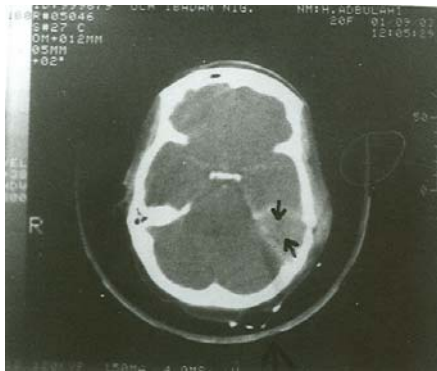**Figure 1c** Photomicrograph of the excised tumour showing invasive squamous cell carcinoma. Magnification is x 40.

The patient was negative on screening for Human Immunodeficiency Virus (HIV) using western Blot technique. Within ten days, a recurrence of the growth was noticed in the left EAC.

Post-operative computerised axial tomography scan (CT Scan) of the brain and petrous bone revealed a large soft tissue mass in the middle ear and mastoid extending superior to the occipital region of the brain and inferiorly to destroy the body of the first cervical vertebra (C1) on the left, left zygoma and temporo-occipital bone. There was destruction of the left petrous bone and sella. The ventricles were within normal limits (Figure 1d and 1e).



**Figure 1d** Computerised axial tomographic scan of the temporal bone showing extensive fleshy tumour involving the middle ear, mastoid and destroying the petrous temporal bone. There is lateral displacement of the left auricle due to the soft tissue swelling.



**Figure 1e** Computerised axial tomographic scan of the brain showing extension of the tumour into the left temporal lobe

The patient was commenced on palliative external beam radiotherapy from  $\text{Co}^{60}$  1.25MeV energy. A direct lateral field encompassing the EAC, mastoid process with lower border at the angle of the jaw to the depth of 3cm was exposed to 30Gy in 10 fractions over two weeks.

She was discharged home on completion of radiotherapy. At discharge, there was gross reduction in the mastoid swelling and significant improvement in the neck stiffness and facial palsy, with considerable pain relief achieved. The patient was subsequently lost to follow-up.

## Case 2

A 45-year old Nigerian male presented to our Otorhinolaryngology clinic with recurrent left hemopurulent ear discharge of four year duration. There was associated left otalgia, tinnitus and hearing loss. There were no associated nasal or

throat symptoms although he was known hypertensive.

Clinical examination revealed a febrile and toxic patient with granulation tissue completely occluding the left EAC. There was a massive left mastoid abscess extending to the pre-auricular and zygomatic area. The right ear, nasal and oral cavities, and oropharynx appeared normal. There were palpable bilateral submandibular and jugulodigastric lymph nodes.

The plain radiograph of the mastoids revealed sclerosis of left mastoid air cells, with a soft tissue mass shadow within the left EAC. The right mastoid appeared normal. No skull base defect was seen.

An incision and drainage of the left mastoid abscess was done immediately followed by left radical mastoidectomy. The histology of the mastoid specimen revealed an invasive keratinizing squamous cell carcinoma.

Following mastoidectomy, he was commenced on external radiotherapy to the left middle ear and mastoid using anterior oblique and posterior oblique fields with a dose of 40Gy in 12 fractions over 4 weeks.

A year later, he developed recurrence of the carcinoma and had palliative radiotherapy of 20Gy in 6 fractions with 6 courses of intravenous 50mg Cisplatin and 1 gm of 5-fluorouracil. Three months later, he developed left facial nerve paralysis with intracranial extension shown by CT scan of the petro-mastoid. The patient eventually died two and half years after initial diagnosis.

## DISCUSSION

Malignant tumours of the middle ear occurring before the fifth decade of life, as seen in the two patients presented, are usual. The peak age at presentation from previous reports has been between the fifth and sixth decades of life<sup>1-3</sup>. There has been no prior report of squamous cell carcinoma of the middle ear from Nigeria.

Chronic suppurative otitis media (CSOM) appears to be a common associated factor in both patients. However, we encountered a dilemma of diagnosis in the two cases. A misdiagnosis of mastoid abscess and meningitis complicating CSOM was made initially, but histopathologic evaluation revealed squamous cell carcinoma. This further emphasizes the importance of submission of all mas-

toid tissues removed at mastoidectomy for histological confirmation of provisional clinical diagnosis, however typical the clinical presentation may appear to be. The features of meningitis seen in these patients were presumably due to meningeal invasion in the course of intracranial extension of malignant cells and cervical vertebral involvement in Case 1, as confirmed by CT scan. Intracranial spread of tympanomastoid tumours may occur through the thin wall of the tegmen tympani or posteriorly to the posterior fossa dura through the mastoid antrum. The infiltration of the lower four cranial nerves.

The fever could be explained by the direct or indirect effect of plasma G-CSF, interleukin 1 and Tumour Necrosis Factor (TNF) released by the activated monocytes, polymorphonuclear leukocytes and the fixed tissue cells of the lymphoreticular system<sup>4,7,8</sup>. They mediate an array of metabolic, endocrine and immunological responses common to the acute phase inflammatory response<sup>4,7,8</sup>.

Most authorities agree that a combination of surgery and radiotherapy as opposed to single modality treatment is likely to yield the best results<sup>9-11</sup>. However in cases of advanced presentation as seen in these patients, the goal of treatment is palliation.

The first patient was offered primary radiotherapy because the disease was already advanced at presentation. There was extensive intracranial extension with complete destruction of the petrous bone and dura, and cervical vertebral involvement coupled with poor general condition of the patient, so the disease was incurable. In addition, the risk of spinal cord transaction is high while maneuvering the neck at endotracheal intubation and surgery. Hence surgery could not be offered. More so, the 5-year survival using either surgery or radiotherapy is 30-35% though morbidity from primary surgery is greater<sup>1,2</sup>. In contrast, the second patient was offered primary surgery and adjuvant radiotherapy and chemotherapy at the first presentation followed by palliative radiotherapy. This is because at the first presentation it was an early disease localized within the mastoid and tympanum and largely extracranial, hence radical mastoidectomy. This has the merit of excising most if not all of the disease and facilitates success of the radiotherapist. The surgical options may range from radical mastoidectomy to subtotal petrosectomy depending on the extent of the disease. cerebrospinal fluid leakage, meningitis and damage to the last four cranial nerves are major complications of

the mastoid carcinoma surgery, though these were not encountered. However, it is difficult to be certain about treatment results for mastoid squamous carcinoma from the literature. Lewis<sup>12</sup> gave an overall cure rate of 27% while Godwin and Jesse<sup>13</sup> reported 29%.

In a review of the outcome of radiotherapy as the primary treatment for this condition, the 5-year survival in 56 patients was 32% for radical and palliative therapy, with an excellent response in early cases<sup>11</sup>. The complications of radiotherapy include severe otalgia, otorrhea and sequestration of bone due to osteo-radionecrosis of the temporal bone.

In conclusion, these cases of squamous cell carcinoma of the mastoid were reported to highlight the young age of the patients, the mimicking of mastoid abscess and meningitis and the aggressive course of the disease. It is hoped that this will prompt a search and early detection of the cases by other workers.

## REFERENCES

1. Martinez Subias J, Dominquez Ugidos LJ, Urpegui Garcia A, Sancho Serrano E, Royo Lopez J, Millan Guevara J, Valles Verela H. Middle ear carcinoma. *Acta Otorhinolaryngologica Espanola* 1998; 49: 234-246.
2. Maran AGD, Jacobson I. Tumours of the ear in: Maran AG, Stell PM Ed: *Clinical Otolaryngology* 3<sup>rd</sup> Edition. Blackwell Scientific Publications 1990; 35: 464-474.
3. Newhart H. Primary carcinoma of the middle ear: report of a case. *Laryngoscope* 1917; 27: 543-555.
4. Pizzo PA, Freifeld AG, Meyer J and Walsh T. Infection in the cancer patient in: DeVita VT, Hellmann S and Rosenberg SA. *Cancer: Principle and practices of oncology*, 4<sup>th</sup> Edition 1993; 62: 2292-2528.
5. de Filippis C, Marioni G, Tregnaghi A, Marino F, Gaio E, Staffieri A. Primary inverted papilloma of the middle ear and mastoid. *Otol Neurotol* Jul 2002; 23(4): 555-559.
6. Cortesina G, De Stefani A, Galeazzi E, Cavallo GP, Badellino F, Margarino G, Jemma C, Forni G. Temporary regression of recurrent squamous cell carcinoma of the head and neck is achieved with a low but not

- with a high dose of recombinant interleukin injected perilymphatically. *Br J Can Mar* 1994; 69(3): 572-576.
7. Morton DL and Economou J. Cancer immunobiology and immunotherapy in: Haskell CM Ed: *Cancer treatment* 3<sup>rd</sup> edition. WB Saunders Company 1990.
  8. Kurihara H, Tamaka K, Yoshitsuru H, Nishio M, Aikawa K, Yawashiro KA case of middle ear carcinoma with high plasma G-CSF level. *J Otorhinolaryngol Soc Jap* 1993; 96: 415-420.
  9. Lewis JS. Surgical management of tumours of the middle ear and mastoid. *J Laryngol Otol* 1983; 97: 299-311.
  10. Maran AGD, Gaze M, Wilson JA. Tumours of the ear: In Stell and Maran's *Head and Neck Surgery*. 3<sup>rd</sup> edition. Oxford: Butterworth-Heinemann 1993; 199-212.
  11. Birzgalis AR, Keith AO, Farrington WT. Radiotherapy in the treatment of middle ear and mastoid carcinoma. *Clin Otolaryngol Allied Sci* 1992; 17: 113-116.
  12. Lewis JS. Temporal bone resection. Review of 100 cases. *Arch Otolaryngol* 1975; 101: 23-25.
  13. Godwin WJ, Jesse RH. Malignant neoplasms of the external auditory canal and temporal bone. *Arch Otolaryngol* 1980; 106: 675-679.
-