

## CORRESPONDENCE

### EMPLOYMENT OF COLOUR FLOW DOPPLER TO IDENTIFY THE TIP OF THE NEEDLE DURING ULTRASOUND GUIDED NERVE BLOCKS

Identifying the needle tip during ultrasound guided procedures such as nerve blocks or vascular access can be a problem. "Visualising the needle tip on ultrasound requires that it be aligned with the ultrasound beam; however even when alignment is achieved, the physical characteristics of the needle and the limitations of ultrasound technology may hinder visibility".<sup>1</sup>

Ultra-sound guided needle placement techniques can be performed using either an out-of-plane or in-plane approach as the needle is advanced towards a desired target. During an out-of-plane approach, the needle cuts the plane of imaging transversely and therefore appears as a hyperechoic "dot" on the ultrasound image (Figure 1). It is more difficult to follow the tip of the needle using this technique.

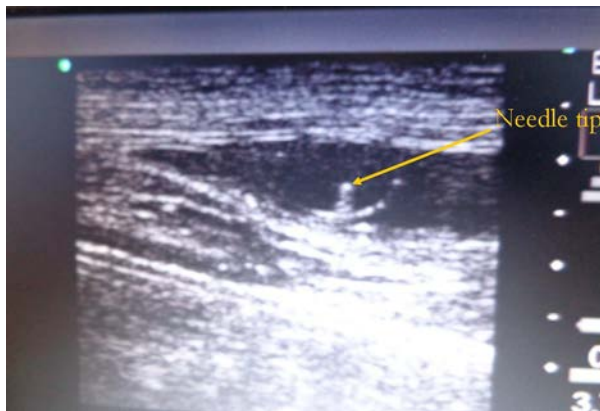


Figure 1: Ultrasound image of needle tip in out-of-plane approach.

Using the in-plane approach, the needle is inserted parallel to the long axis of the ultrasound probe and therefore lies completely within the plane of imaging. The needle is therefore seen as a hyperechoic line on the ultrasound image (Figure 2).

Regional nerve blocks require precision to deliver local anaesthetic drugs very close to nerves while avoiding damage to the nerves and surrounding structures. The standard approach therefore is an in-plane technique where there is visualisation of the long axis of the needle and the needle tip is better tracked.<sup>2,3</sup> It is our experience that the task of aligning the needle in-plane can frequently be painstaking and time consuming; more so, in the hands of less experienced trainees.

It is therefore, necessary to employ other manoeuvres that will improve the ease of identification of the needle tip during insertion.

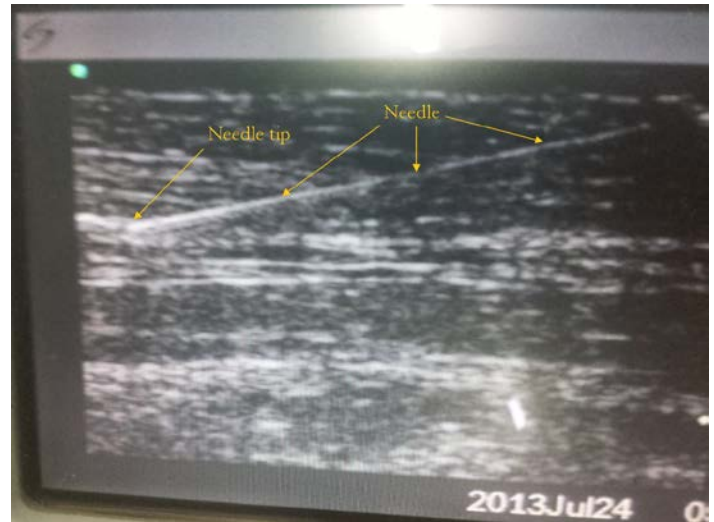

Figure 2: In-plane ultrasound image of needle.

Fig 2 is a 2D image showing the needle. Fig 3 is taken in the colour flow Doppler mode and it shows the colour flow image at the tip of the needle.

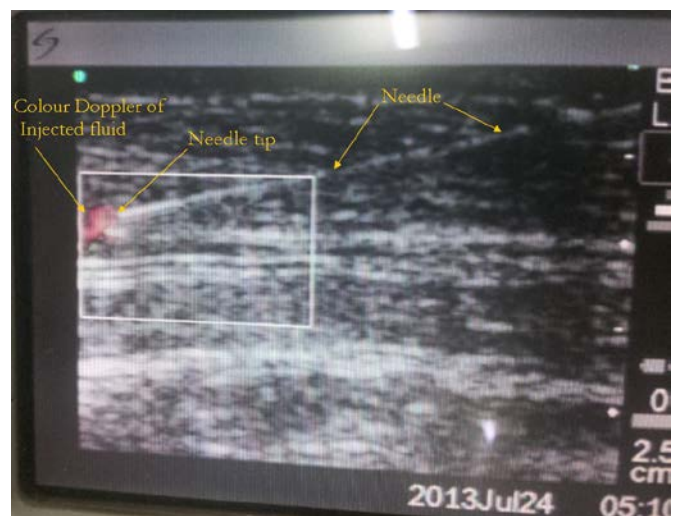

Figure 3: Colour flow Doppler image of needle.

While practicing ultrasound guided manipulation for nerve block techniques on a tissue model (portion of porcine anterior abdominal wall), we have employed colour flow Doppler combined with rapid injection of small boluses (approx. 0.3ml) of fluid through the needle to identify the tip of the needle. With the ultrasound in the 2D mode, using an in-plane technique, the needle is aligned as best as possible with the ultrasound beam. The ultrasound mode is then changed to colour flow Doppler and using a 3-ml syringe, approximately 0.3-0.5 ml of fluid is injected rapidly through the needle. A colour image is produced at the needle tip where the fluid exits the needle, thus making it possible to identify the position of the needle tip.

We think this manoeuvre affords a reliable visualisation of the needle tip in ultra-sound guided needle placement techniques and that it may have some value in clinical practice. Further studies to evaluate the clinical usefulness of this technique could be considered.

**Henry Baddoo MBChB, FRCA, FRCSEd, FWACS, FGCS.**

**Robert Djagbletey MBChB, DA(WACS), FGCS.**

**Christian Owoo MBChB, DA(WACS), FGCS.**

**Department of Anaesthesia, Korle Bu Teaching Hospital, Accra, Ghana**

**E-mail: hbaddoo@yahoo.com**

## REFERENCES

1. Chin KJ. Needle and transducer manipulation: The art of Ultrasound-guided Regional Anaesthesia. *International Journal of Ultrasound and Applied Technologies in Perioperative Care* 2010;1(1): 27-32.
2. Stone MB, Price DD, Wang R. Ultrasound-guided supraclavicular block for the treatment of upper extremity fractures, dislocations, and abscesses in the ED. *Am J Emerg Med* 2007;25(4):472-5.
3. Blaivas M, Lyon M. Ultrasound-guided interscalene block for shoulder dislocation reduction in the ED. *Am J Emerg Med* 2006;24(3):293-6. □