

MASSIVE PERSISTENT LOWER GASTROINTESTINAL HAEMORRHAGE SECONDARY TO TYPHOID FEVER: A CASE REPORT

*N. A. ADU-ARYEE, H. K. ADUFUL AND F. EDWIN
Department of Surgery, University of Ghana Medical School, Accra

SUMMARY

We report a case of massive lower gastrointestinal bleeding secondary to typhoid fever. The diagnosis was essentially clinical. The patient was managed surgically. This involved segmentation of the ileum with soft bowel clamps, enterotomy and under-running of an identified arterial bleeding site. The patient made an uneventful recovery.

Keywords: Segmentation of the ileum, soft bowel clamps, limited stock of blood, under-running.

INTRODUCTION

Massive lower gastrointestinal bleeding secondary to typhoid fever has traditionally been managed conservatively. This is primarily due to the fact that bleeding is usually from several ulcerated Peyer's patches and is, most of the time, self-limiting. There is abundant evidence that surgical management by segmental ileal resection or formal right hemicolectomy offers another mode of treatment of this condition^{1,2,3,4,5,6}.

There are reports, which indicate the efficacy of radiological intervention for the control of bleeding. This involves superior mesenteric angiogram followed by instillation of vasopressin^{6,7,8} or insertion of gelfoam coils to vasoconstrict the offering vessel or thrombose it respectively.

CASE REPORT

A 32-year-old male was seen with a six-day history of fever, headache, vomiting and abdominal pain. He also had a day's history of massive bright red bleeding per rectum. Other symptoms included chills, rigors, joint pain and anorexia. He was in shock with a weak and thready pulse and a blood pressure of 90/50 mmHg. There was mild tenderness in the right iliac fossa and rectal examination showed bright red blood. A Widal test done by the referring doctor showed *Salmonella typhi* O and H antibody titres of 1/320 and 1/320 respectively

upon which treatment for typhoid fever was commenced with oral chloramphenicol 500mg 6 hourly. A diagnosis of shock secondary to massive bleeding from typhoid fever was made. Laboratory investigations done showed an haemoglobin of 3g/dl, white cell count of $4.2 \times 10^9/l$, platelet count $198 \times 10^9/l$, and a negative sickling status. Blood urea and electrolytes were normal. Cultures for *Salmonella typhi* and a repeat Widal were not due to inadequate laboratory facilities at the time presentation.

He was initially managed with intravenous crystalloids followed by transfusion of four (4) units of blood and was also given intravenous ciprofloxacin. Initially, he appeared to be responding to treatment but over the next twenty-four hours he passed five large amounts of fresh blood per rectum and on each occasion became haemodynamically unstable.

In view of the limited blood supply in the hospital and the obvious failure of conservative management, a decision was taken to operate.

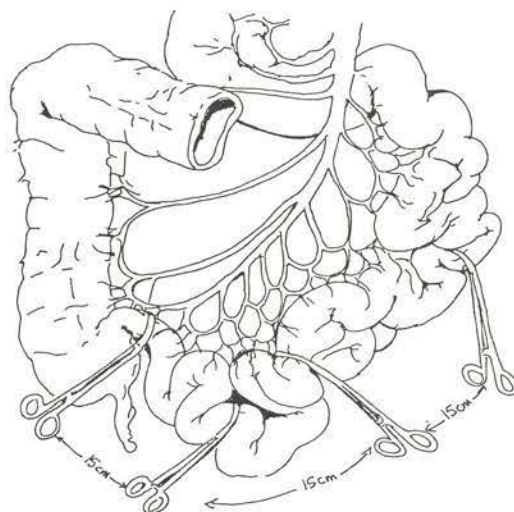


Figure 1 Segmentation of the ileum with soft bowel clamps

* Author for correspondence

At operation inflamed and swollen Peyer's patches were noticed. The ileum and the large bowel were filled with blood. There was no blood in the jejunum. The ileum was initially emptied of its content by milking into the caecum. Soft bowel clamps were then applied across the ileum at interval of fifteen centimeters (15cm) from the ileocaecal valve to break the ileum into segments.

The distal segment was found to fill rapidly with blood while the other segments remained collapsed. Two Peyer's patches were found in this segment 5 and 10 centimetres from the ileocaecal valve. A longitudinal enterotomy was performed between the two inflamed Peyer's patches and a spurting arterial bleeding was found at the lateral edge of an ulcerated proximal peyers patch.

The bleeding vessel was under-run with chronic catgut 2/0 to stop the bleeding. The enterotomy was then closed in two layers with vicryl 2/0. The ileum was not friable. The bleeding stopped promptly and the patient subsequently made an uneventful recovery. He was discharged in relatively good health on the sixth postoperative day.

DISCUSSION

Conservative approach is usually adopted for the management of haemorrhage from typhoid fever. Operative approach^{1,2,3,4,5,6} is also well established and the use of interventional radiology techniques^{6,7,8} adds to the armamentarium for the management of this condition. Reported rates of bleeding from typhoid fever varies between 1 to 13%. Conservative management has a few drawbacks; chiefly among these being the limited stocks of blood in most hospitals in areas where typhoid is endemic. There is also the added risk of increased incidence of transmission of HIV and hepatitis B if massive blood transfusions are given. This makes early surgical intervention in massive bleeding worthwhile.

Most surgical interventions take the form of either segmental ileal resection, or right hemicolectomy, which involves the loss of the ileocaecal valve. Resection of the terminal ileum may also deprive the patient of a vital absorptive function of this organ and if resection is performed too near the ileocaecal valve anastomotic leaks are more common.

We believe that in the absence of emergency angiography in the sub region, operative intervention using the segmentation technique we have described to identify and deal with the source of

bleeding is indicated. Indications will include uncertain diagnosis, unsatisfactory blood banking facilities, continuous bleeding requiring more than four units of blood in 24 hours, shock, and associated perforation.

We also believe that under-running the bleeding point is a safe procedure if the bleeding point is single, very near the ileocaecal valve and can be identified by the segmentation technique. If multiple bleeding sites are identified by this method then a formal ileal resection or right hemicolectomy is advised.

REFERENCES

1. Eggleston F.C, Santoshi B. Treatment of typhoid ulcer of the terminal ileum and caecum. *World J of Surg* 1981; 5: 295-297.
2. Holmgren G. Severe intestinal haemorrhage in typhoid. A case report. *Central Afr J of Medi* Dec 1973; 19: 12
3. Strate H.W., Banayan G.A. Typhoid fever causing massive lower gastrointestinal haemorrhage. A reminder of Things Past. *JAMA* Oct 1976; 236: 17.
4. Wong S.H. The emergency surgical management of massive and persistent intestinal haemorrhage due to typhoid fever: A report of 3 cases. *British J Surg* 1978; 65: 74-75.
5. Wig J.D., Malik A.K., Khanna S.K. et al. Massive lower gastrointestinal bleeding in patients with typhoid fever. *America J Gastroenterology* Jun 1981; 75(6): 445-448.
6. Reyes E., Hernandez J., Gonzalez A. Typhoid colitis with massive lower gastrointestinal bleeding. An unexpected behaviour of *Salmonella typhi*. *Dis Colon Rectum* (United States). Aug 1986; 29(8): 511-4
7. Vaidya A., Supe A., Samsi A.B., Ramakantan R. Continuous intra-arterial vasopressin infusion for the control of typhoid haemorrhage. *Indian J Gastroenterology* 1990; 9(3): 225-226.
8. Delamarre J., Capron J.P., Fievet P. et al. Bleeding cecal typhoid ulcer. Value of emergency angiography for selective surgical hemostasis. *Hepatogastroenterology* Dec 1983; 309(60): 266-7.